

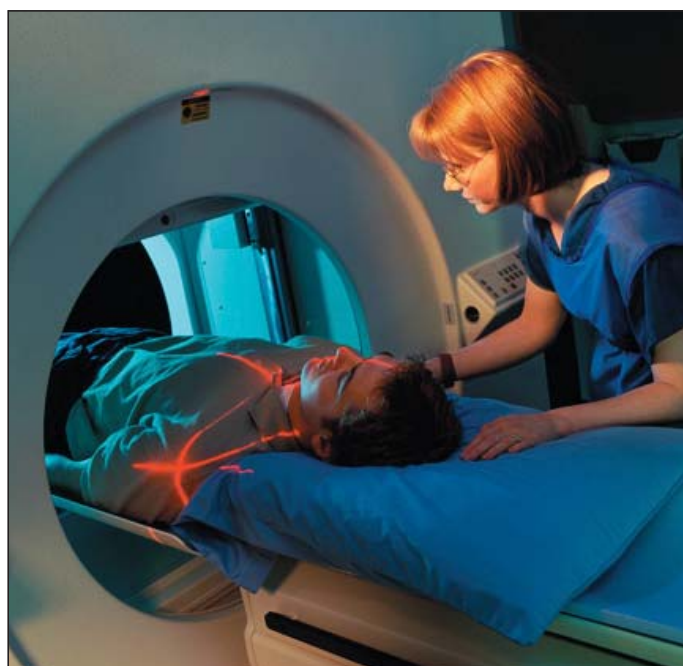Full-Body CT Scanning - Prevention at What Cost?

Ian Hunter

For many cancer patients, an early diagnosis can make the difference between an untreatable illness and successful survival. Pre-symptomatic diagnosis can be achieved using computed tomography (CT) where x-rays detect differences in the density of body tissue, and hence identify abnormalities such as malignant tumours. The notion of a CT procedure that takes less than 15 minutes, providing either the reassurance of health or the preliminary indication of disease, is one that can hypothetically be viewed with optimism. The full-body CT scan, whose popularity has boomed in the past decade (1), enables this notion to approach reality. Clinics offering these examinations can be found worldwide but are particularly common in the USA. This method offers diagnoses of potentially life-threatening diseases, but despite the potential benefits, the full-body CT examination has recently been the source of much scepticism and controversy, receiving a considerable amount of criticism from medical authorities. The debate concentrates on medical, legal and financial issues but do the drawbacks outweigh the advantages?

And how will continuing speculation and pessimism affect the development of full-body CT as a plausible screening procedure?

Since its advent in the 1970s (for which Hounsfield and Cormack were awarded the Nobel prize for medicine), CT has been widely accepted and used to perform 'targeted' examinations that confirm or reject diagnoses made for symptomatic patients. The major advantage of CT is that it is faster and less invasive than surgical methods. Also, CT differentiates between tissues of closer densities than the simpler projection x-ray technique and therefore can pick out less advanced abnormalities. However, the radiation dose provided by CT is considerably larger than that of a projection x-ray and is equivalent to several years of natural background radiation (which includes charged solar particles and terrestrial radioactive isotopes such as potassium-40 and carbon-14). The entire global population receives an essentially constant dose of between 1.5 and 7.5 mSv per year from background radiation, while a targeted CT examination provides between 2 and 10 mSv (unit of radiation dose equivalent), and a projection x-ray gives only 0.02 mSv (2). However, it is generally agreed that the benefits of a 'targeted' procedure, carried out when a positive finding is expected, outweigh the risks associated with the exposure to such a dose (2).



Full-body CT examinations, on the other hand, are targeted at asymptomatic patients. Depending on the particular clinical question, images of the patient's head, abdomen, thorax and pelvis are obtained and scrutinised for possible abnormalities. Centres offering full-body CT scans advertise a potentially "life-saving" service that can, "in a matter of minutes", screen a patient for a large number of latent conditions. One centre states that its scans can detect both early and developed indications of diseases of the heart and lungs as well as "kidneys, spine, liver, pancreas, gall bladder, thoracic aorta, abdominal aorta, adrenal glands, lymph nodes, spleen, and certain pelvic organs" (4).

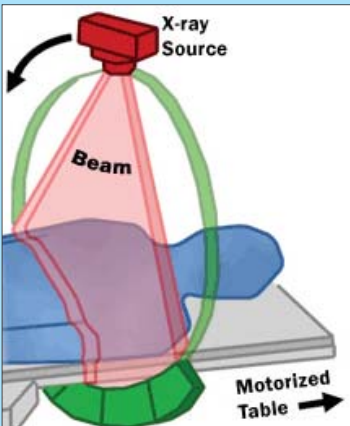
It is widely asserted that the rise in untargeted full-body CT examinations is a result of a growing interest in healthy living that has also involved increased attention towards the physiological impact of certain foods and growing awareness of the symptoms of common illnesses (1). This increasing concern is linked to the emergence of the class commonly known as the "worried wealthy", where people want, and are able to afford, a procedure that offers possibilities of reassurance or early diagnosis (5).

It could be suggested that another factor in CT's growing reputation is its appearance in popular culture, particularly on television. In 2000, full-body CT featured on *The Oprah Winfrey Show*, America's number one talk show, and was portrayed in an overall positive light. Oprah Winfrey underwent a full CT examination, which was described as "a miraculous look inside the body" that allows patients to be "empowered" by the knowledge gained from a single study. It is understood that the popularity of full-body CT scans rose greatly following the show (6). Conversely, full-body CT also appears less favourably in an episode of the popular television series *Scrubs*, in which the characters discourage others from having a scan, criticising the method for being "sketchy ethically", "invasive and often pointless" (7). It is difficult to ascertain to what extent these appearances influenced popular opinion, but it is likely that they have raised the profile of CT screening and fuelled the associated debate.

The wide and complex debate surrounding CT screening is heightened because it does not meet some of the globally-established criteria set out to ensure screening methods are conducted appropriately. The criteria, formed for the World Health Organisation in 1968 by Wilson and Jungner,

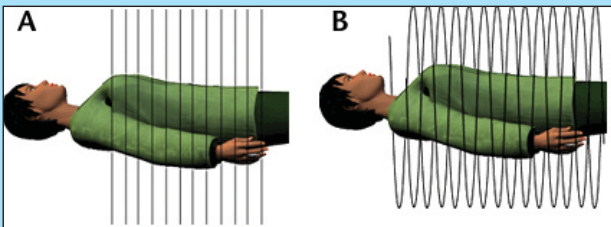
CT Scanning Explained

During a CT examination the patient lies inside a ring around which an x-ray tube and an arc of detectors rotate. To produce one of the 'slices' required for an



image, the rotating set-up completes a 360° revolution while emitting x-rays. Tissues of different densities cause varying attenuation of these x-rays (i.e. molecules in the tissue weaken the x-ray beam by dispersing and absorbing the radiation). The transmitted x-ray intensity depends on the degree of

attenuation in the body and can therefore be used to locate tissues of different densities. A complete CT examination is composed of several hundred individual slices at different positions along the patient's body. The slices are subsequently combined electronically to generate a 2D cross-sectional image.



Recently, CT scanning has been accelerated by the development of helical (or spiral) CT machines in which the x-ray tube and detector move continuously around the patient tracing out a helix. The duration of the procedure has been further decreased by combination of this with multiple row detectors, where several x-ray beams fan out in three rather than two dimensions and are received by several rows of x-ray detectors, enabling more than one slice to be scanned simultaneously.

clearly state that any screening procedure should only be authorised if there is "a detectable early symptomatic stage of disease" and if "the disease is an important public health problem" (8). These criteria are unfulfilled by full-body CT screening, as its primary target group show no symptoms. Further criteria, which elaborate on those by Wilson and Jungner, were released in 2003 and specify that a screening test should be "safe and precise" and the benefits of the test "should outweigh the physical and psychological harm caused" (9). Whether these criteria are met by full-body screening is doubtful.

Nevertheless, there are certain universally agreed benefits. The procedure itself is completely unobtrusive and

takes less than one hour to perform. The images produced are extremely impressive; they have a high resolution, typically 0.1 – 2.0mm, and can be reformatted in any desirable plane. As a consequence, if an accurate full-body scan is deemed necessary, then CT undoubtedly produces some of the best images for the purpose. And of course, as endorsements from CT screening centres state, the method has provided a life-saving service for some clients, whose scans have highlighted medical conditions that would otherwise have remained undiscovered (10). However, it is difficult to find details of such patients in neutral studies into full-body CT scanning, suggesting that the relatively few success stories are overwhelmed by the risks that dominate the debate.

Arguably the largest medical risk involved with full-body, and indeed all CT, scanning, is exposure to a significant dose of ionising radiation, causing great uncertainty as to whether the procedure fulfils the WHO criterion for a "safe" test. As mentioned above, a targeted CT examination provides a dose of between 2 and 10 mSv whereas it is estimated that a typical full-body examination gives a much higher 12 mSv. Authorities on the subject have compared such doses with those received by people only 2 km from the epicentre of an atomic bomb explosion. Research has shown that the cancer risk to atomic bomb survivors at this distance is approximately 0.08% above the natural risk. Therefore, it has often been stated that for every 1250 patients who receive full-body CT examinations, one will consequently develop cancer. Furthermore, the effect of multiple CT examinations is cumulative, so receiving an annual CT for thirty years gives a one in fifty chance of developing cancer purely as a result of the procedure. Understandably, medical authorities have been keen to encourage the "worried wealthy" not to undergo any CT examination without due consideration (11).

The reliability and precision of CT screening is also far from perfect. Patients often see a full-body CT examination as a route to reassurance of fine health; they enter the clinic seeking the all clear. If they receive this, they may in future believe that they do not need to undergo other more widely recommended and well-established procedures that screen more specifically, such as mammograms and cervical screening. Many medical professionals believe this is dangerous due to the possibility of false negatives where preliminary abnormalities are not detected and the patient is left with a false sense of security. If the patient then ignores symptoms, believing in the all-clear, the disease may be allowed to develop to a less treatable stage. CT procedures are also unable to detect certain tumours or lining erosion and cannot convey how well an organ is functioning (12). Dr. Leonard Berlin at Rush North Shore Medical Center warns that false negatives results can occur because of systematic error and because contrast media, which produce a more clearly defined image and without which some tumours will not show up, are not routinely used in full-body screening (13). With such crucial omissions from the list of the technique's capabilities, it seems important that patients understand that a full-body CT examination is not all-encompassing and should be supplemented by other methods even if their clean bill of health is confirmed.

In addition to the high chance of false negative results, full-body CT screening intrinsically produces a large number of false positive results where abnormalities are detected which, on further investigation, transpire to be harmless. Examples

of such findings include benign tumours, cysts, scar tissue and lung nodules - a common occurrence among smokers. The further investigations are often expensive, subjecting the patient to stressful, unnecessary, invasive procedures. A report published in *Radiology* into the cost-effectiveness of full-body scanning estimates that a false-positive result occurs in approximately 91% of scans. This implies that for every ten CT examinations carried out, nine produce a result that compels the patient to undergo unnecessary further tests (14). This figure is echoed by other studies in the subject (15) and is a by-product of the method's sensitivity to tissues of subtly dissimilar densities: any tissue appearing at all abnormal compared to its surroundings will yield a positive result (like those listed above).

Despite such a high proportion of false positive results, there has been little evidence of any high-profile legal cases involving full-body CT screening. However, in today's "compensation culture" (16), if the level of inaccurate results remains high, it is possible that this will change and that patients will begin to exploit their pointless suffering from tests following false positives by taking legal action against the centre that offered and performed the study. Leonard Berlin has performed an extensive investigation into the legal ramifications of full-body CT screening and asserts that "patients who sustain... complications and injuries from medical procedures that... were performed due to an 'abnormality' seen on CT screening that later turned out to be insignificant may be apt to pursue litigation" (17). Litigation would also be a possibility should patients develop cancers following radiation exposure, though this would be rare given the difficulty in proving that the CT examination itself caused the tumour to develop. However, if the public is made aware of the clear risks involved and their awareness is documented then such action can be minimised (18). Whether any lawsuits will arise is open to much discussion. Berlin compares full-body CT screening to Pandora's Box, suggesting that the whole field contains "a host of medical malpractice ills" that might be "unleashed into the radiology community" but which equally could fail to emerge (17).

Uncertainty also exists regarding the financial side of full-body CT screening, and, most notably, who should pay for subsequent investigations after a positive result. It

**A false-positive result
occurs in approximately
91% of scans**

is generally accepted that the patient should pay for the initial examination (a further drawback of CT screening as an individual examination costs up to \$1000) but insurance, both public and private, currently pay for the majority of biopsies and investigatory surgery that can ensue. However, is it correct that the public should pay for procedures that so often prove to be pointless? Or is it fair to deprive those who do require immediate attention just because someone else's treatment turns out to be unnecessary?

Among medical authorities the consensus about full-

body CT screening is overwhelmingly negative, with positive portrayals only evident from the CT screening centres themselves. There are benefits but as discussed above they are greatly outweighed by the disadvantages. Investigations

into the subject reveal that the radiation risk is too high to ignore, that the results of scans are too inaccurate to eliminate false negative results and, paradoxically, too accurate to eliminate false positives causing much

stress and financial strain. And perhaps the most significant criticism is that the full-body screening process fails to meet at least four of the WHO criteria which ensure that all screening procedures are used with the safety of and benefit to the patient as the main concerns. Manufacturers continue to develop more advanced CT machines, producing ever-improving images, and yet the full-body CT scanning process is heavily criticised, particularly with the concurrent development of the far safer full-body MRI (magnetic resonance imaging). Full-body imaging has seen a rapid boom in the past decade, but one can only foresee a symmetrical recession.

Ian Hunter is a 2nd year at Downing College reading Physical Natural Sciences, specialising in Chemistry and Materials Science.

References:

1. Baker, S. *American Journal of Roentgenology*, **180**, 27-30, (2003)
2. Allan, P. Royal College of Physicians of Edinburgh, 2004, <http://www.behindthemedicalheadlines.com/articles/full-body-ct-scans-are-they-worth-the-cost-in-money-and-radiation-exposure>
3. Barclay, L. *Medscape*, 31 August 2004. medscape.com/viewarticle/488260?rss.
4. ScanDirectory.com, 2007, scandirectory.com/content/body_scan.asp.
5. American Institute of Physics, 26 August 2002, aip.org/isns/reports/2002/052.html.
6. Bonn, D. *The Lancet Oncology*, **5** (10), 586, (2004)
7. NBC, *Scrubs*: Episode 3.20 (Prod # 320), (2004)
8. Wilson J.M., Jungner G. *Principles and practice of screening for disease*, Geneva: World Health Organization, 1968. Public Health Paper Number 34.
9. National Screening Committee, March 2003, <http://www.library.nhs.uk/screening/viewResource.aspx?resID=59772>
10. Be Well Body Scan, Patient Stories, 2004, bewellbodyscan.com.
11. Brenner, D., Elliston, C. *Radiology*, **232**, 735-738 (2004)
12. UCI Medical Center, "Inner Explorations" 2001, ucihealth.com/News/UCI%20Health/InnerExplorations.htm
13. Merle, A. *Greenberg Radiology Imaging*, 2 May 2002, greenbergradiology.com/news/article.htm
14. Beinfeld, M., Wittenberg, E., Gazelle, G. *Radiology*, **234**, 415-422, (2005)
15. Anderiesz, C., Elwood, J., McAvoy, B., Kenny, L. *The Medical Journal of Australia*, **181**, 295-296, (2004)
16. BBC News, Compensation fears 'gripping UK', 3 November 2005.
17. Berlin, L. *American Journal of Roentgenology*, **180**, 317-322, (2003)